



PATIENT

Riley Randall

SPECIES

Canine

BREED

Labrador Retriever

SEX

Male Neutered

AGE

8 years

WEIGHT

56lbs

PRESENTING CLINICAL SIGNS

History: Riley was noted to have a heart murmur in July. A ProBNP elevated at 1211. Coughs when he gets overly excited or pulls on the leash. Recently noted heart murmur. No labored breathing or exercise intolerance. On exam: arrhythmia, grade II/VI murmur with PMI left apical area, PSS, lung fields clear. BP: 120mmHg x 4. *Sedated with propofol for study.

ECHOCARDIOGRAM FINDINGS

2D, m-mode, color flow and Doppler imaging is available.

Left ventricle: The LV diameter is normal with mildly depressed myocardial function. LV wall thicknesses are normal.

Left atrium: The left atrium is normal.

Mitral valve: The mitral valve is mildly thickened with no prolapse into the left atrial lumen. Mild to moderate eccentric mitral regurgitation with a normal velocity.

Aortic valve/aorta: The aortic valve is normal in morphology and mobility. Normal aortic outflow velocity; laminar flow. No aortic insufficiency.

Right ventricle: Normal right ventricular diameter and morphology indicating no overt evidence of pulmonary arterial hypertension.

Right atrium: Normal RA dimension.

Tricuspid valve: The tricuspid valve appears mildly thickened with trivial tricuspid regurgitation.

Pulmonic valve/pulmonary artery: The pulmonic valve is normal in morphology and mobility. No pulmonic insufficiency. Normal RVOT velocity; laminar flow.

Pericardium/other: No pericardial or pleural effusion noted. No obvious cardiac masses.

Heart rhythm: ECG reveals a sinus rhythm with an average HR of 80bpm.

INTERPRETED BY

Maggie Machen Lamy, DVM DACVIM (Cardiology)

2-Dimensional Measurements

Ao diam (cm)	2.1
LA diam (cm)	2.6
LA:Ao (Swe)	1.2
IVS thickness (cm)	1.1
LVID diastole (cm)	4.6
PW thickness (cm)	1.1
LVID systole (cm)	3.5
FS (%)	24

Doppler Measurements

PV Vmax (m/s)	0.6
AoV Vmax (m/s)	1.4
MR Vmax (m/s)	5.1
TR Vmax (m/s)	NM
TR PG (mmHg)	NA

IMAGING

PERFORMED BY

Pamela Harrigan, RDCS

INTERPRETATION OF THE FINDINGS

The cause of the murmur is chronic degenerative valve disease causing mild to moderate mitral and trivial tricuspid regurgitation. Lack of significant left atrial enlargement indicates the current risk for complication is low. The LV function is mildly depressed, which may be a normal variant, may develop secondary to valve disease or may be secondary to sedation. Recommend rule out any contributing issues, such as a non-traditional diet or hypothyroidism and reassess in the future without sedation. No additional issues such as pulmonary hypertension are noted in this study.

HOSPITAL NAME

Mass Veterinary Services

REFERRING VET

Dr. Masloski

INVOICE

25698

DATE

8/10/22

Assessment of progression in the future will help predict long term prognosis, which is highly variable at this stage (B1).

Given these findings, the cough is unlikely to be cardiac in origin and primary respiratory causes should be considered. Consider further respiratory work up/treatment (hydrocodone, taper course of steroids, Enrofloxacin, TTW/BAL, etc.).



PATIENT

Riley Randall

SPECIES

Canine

BREED

Labrador Retriever

SEX

Male Neutered

AGE

8 years

WEIGHT

56lbs

INTERPRETED BY

Maggie Machen Lamy, DVM
DACVIM (Cardiology)

IMAGING PERFORMED BY

Pamela Harrigan, RDCS

HOSPITAL NAME

Mass Veterinary Services

REFERRING VET

Dr. Masloski

INVOICE

25698

DATE

8/10/22

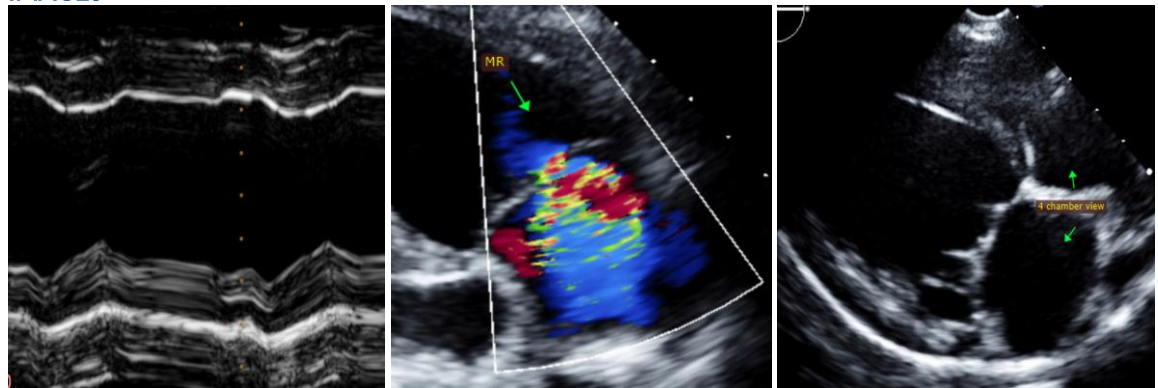
RECOMMENDATIONS

- Given these findings, no cardiac medications are clearly indicated.
- Consider diet/thyroid status as discussed.
- Omega fatty acid supplementation and mild salt restriction may be of some long-term benefit.
- Anesthetic risk is considered mild if needed. Cardiac protective drug choices (opioid/benzodiazepine premedication, propofol or alfaxalone induction, isoflurane gas) are recommended. Pre-oxygenate for 5-10 minutes prior to induction. Monitor for arrhythmias, hypotension, and hypoxia both intra and post-operatively and intervene as necessary. Mild IV fluid restriction is recommended to avoid fluid overload. Avoid heart rate stimulating drugs such as atropine unless clinically indicated.
- Monitor for development of a cough, labored breathing, exercise intolerance or collapse episodes.

PLAN

- Recommend conservative monitoring with a recheck echocardiogram in 6 months, sooner if any development of clinical signs.

IMAGES



The information and recommendations provided are based on the images presented by the referring veterinarian. No evaluation can be communicated regarding pathology that was not visible in the image/video clips provided.

Thank you for this referral. This report was generated using transcription software, and minor dictation errors may be present. If the clinical or image interpretation does not parallel your findings or if I can be of any further assistance, please contact me.

Maggie Machen Lamy, DVM
Diplomate of the American College of Veterinary Internal Medicine (Cardiology)
info@sonopath.com

Echocardiogram performed by: Pamela Harrigan, RDCS
Pet Animal Ultrasound Service (4paus.com)